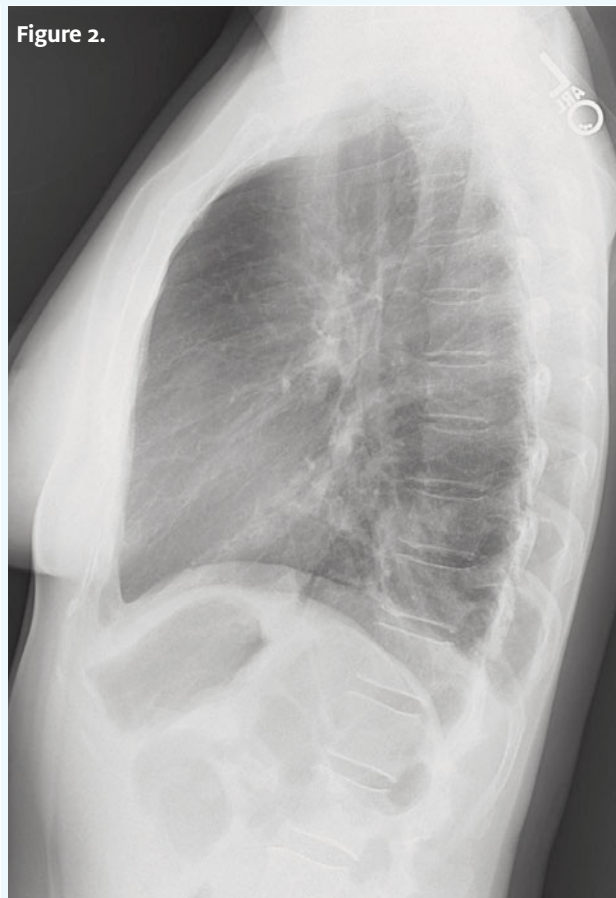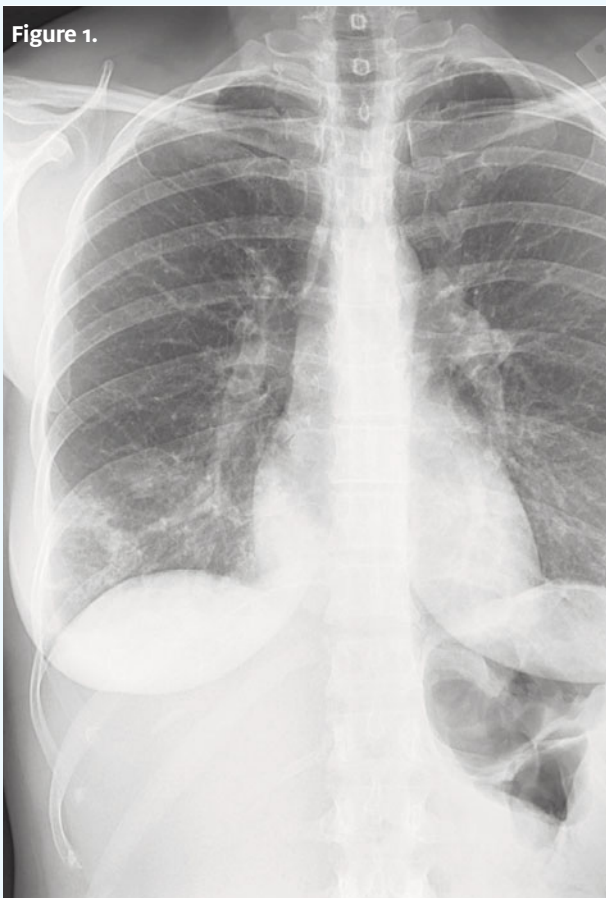




In each issue, *JUCM* will challenge your diagnostic acumen with a glimpse of x-rays, electrocardiograms, and photographs of conditions that real urgent care patients have presented with.

If you would like to submit a case for consideration, please email the relevant materials and presenting information to editor@juqm.com.

A 40-Year-Old Female with Progressively Worse Cough and Fever

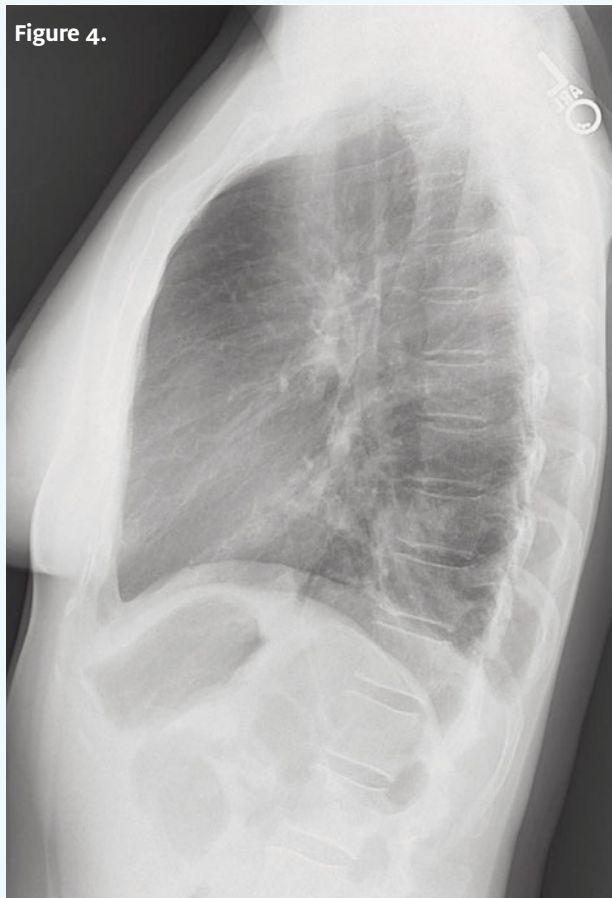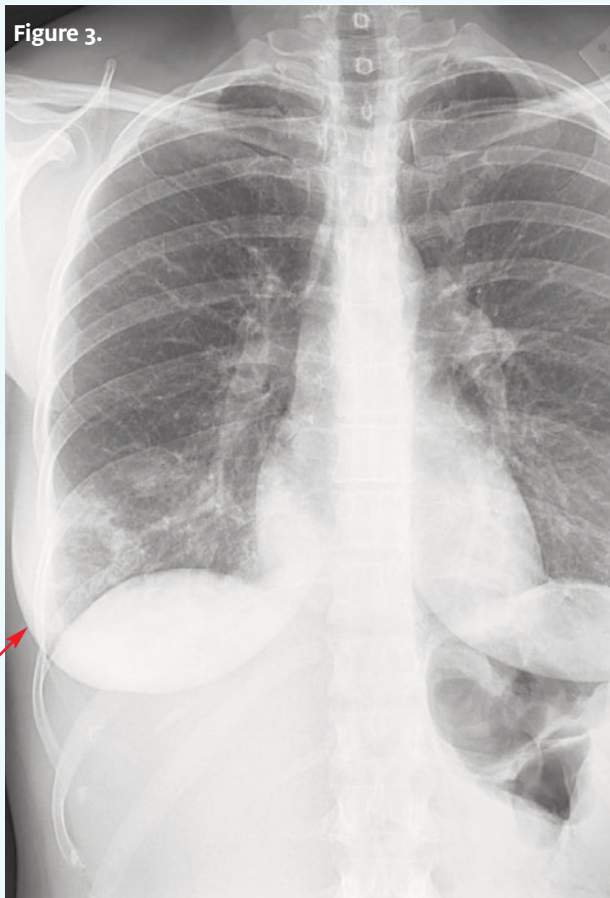


Case

The patient is a 40-year-old woman who presents with cough and fever that has been getting worse “for a few days.” She is a former smoker, and has diabetes mellitus.

View the images taken and consider what the diagnosis and next steps would be. Resolution of the case is described on the next page.

THE RESOLUTION

**Differential Diagnosis**

- Lung abscess
- Pulmonary gangrene
- Necrotizing pneumonia
- Necrotizing pulmonary malignancy

Diagnosis

This patient was diagnosed with necrotizing pneumonia. Examination of the images shows the cardiomeastinal silhouette is within normal limits. Patchy infiltrate is noted in the right lower lobe, concerning for pneumonia. This infiltrate demonstrates a focal area of low density in its lateral inferior aspect, concerning for possible area of either incomplete consolidation or cavitation. An area of cavitation would be concerning for necrotizing pneumonia. No pleural effusions are seen. There is no evidence of pneumothorax. The soft tissue and osseous structures appear unremarkable.

Learnings/What to Look for

- Necrotizing pneumonia is a rare complication of bacterial lung infection due to either the virulence of the microorganism or a predisposing factor of the host
- Complications include diffuse pulmonary inflammation, septic shock, and respiratory failure

Pearls for Urgent Care Management and Considerations for Transfer

- Intravenous broad-spectrum antibiotics are indicated, and should target pathogens that commonly cause necrotizing changes (most commonly such as *Staphylococcus aureus*, *Staphylococcus pneumoniae*, and *Klebsiella pneumoniae*)
- Sometimes pulmonary resection is necessary

Acknowledgment: Images and case provided by Teleradiology Specialists, www.teleradiologyspecialists.com.



A 57-Year-Old Man with a Chief Complaint of Syncope 3 Hours Ago

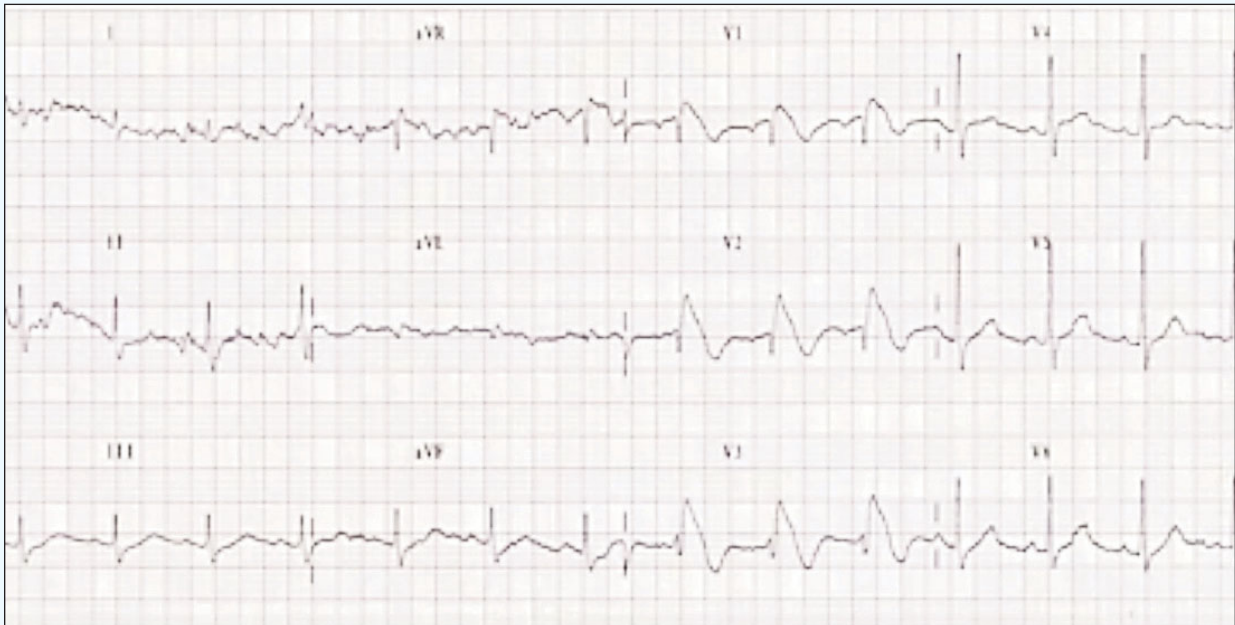

Figure 1.

Case

The patient is a 57-year-old man with a complaint of syncope 3 hours before arrival. He states he was sitting on the couch and the next thing he knew he was waking up. No preceding dizziness. No seizure activity, biting of the tongue, blood in the mouth, or post ictal symptoms. No cp, SOB, leg pain, head pain, or back pain. He drank 2 glasses of water and felt better, but was encouraged to seek urgent care by his family.

Upon exam, you find:

- **General:** Sitting on the cart, pink, skin dry, breathing comfortably and speaking normally

- **Lungs:** Clear bilaterally
- **Cardiovascular:** Regular rhythm, without m,r,g
- **Abdomen:** Soft and NT, no distention, without r/t/g, no pulsatile mass
- **Ext:** No edema or asymmetry, pulses are 2+ and equal in all extremities, no LE pain

View the ECG taken and consider what the diagnosis and next steps would be. Resolution of the case is described on the next page.

THE RESOLUTION

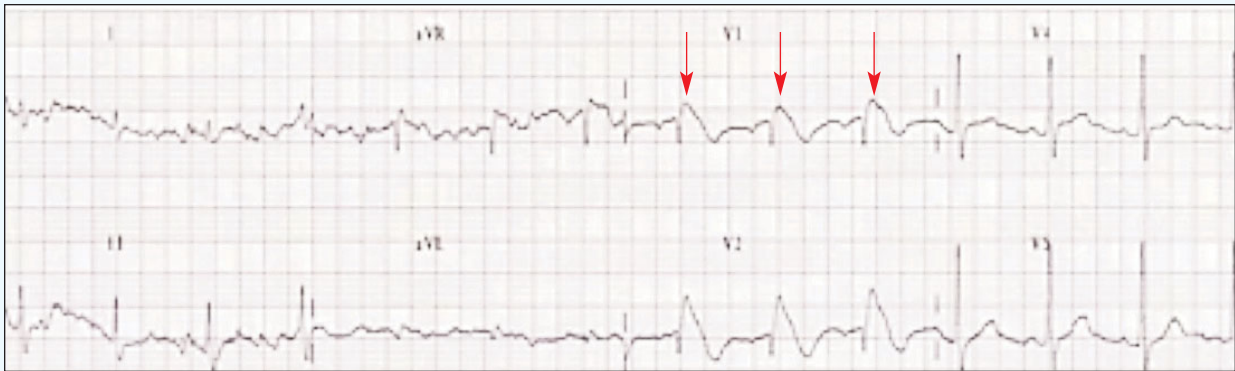

Figure 2. ST elevation with incomplete right bundle branch block (red arrows)

Differential Diagnosis

- First-degree AV block
- Wolff-Parkinson-White syndrome (WPW)
- Anterior STEMI
- Brugada syndrome
- Third-degree heart block

Diagnosis

This patient has Brugada syndrome. The syncope patient who is now “normal” is the classic urgent care encounter; typically all that is needed is a good history and physical *and* an ECG, looking for:

1. Wolff-Parkinson-White
2. Prolonged QT syndrome
3. Brugada syndrome
4. Hypertrophic cardiomyopathy
5. Ischemia or arrhythmia

Regarding the “differential diagnosis” for the ECG above, the normal PR interval is 120-200 ms, with first-degree AV block being a duration longer than 200 ms, not present on this ECG. WPW is defined by a short PR, a delta wave, and a wide QRS complex—again, not present here. Could this be an anterior STEMI? Possibly...but the morphology of the ST segments is different than typically seen with a STEMI; plus, the leads with ST elevation are curious—anterior STEMI generally involves leads V3 and V4, not V1-3, and...in a patient without chest pain, shortness of breath or sweating, this would be a very unusual presentation indeed! The final possibility presented is third-degree heart block, where there is no conduction of the p waves to generate a QRS complex. Third-degree (complete) heart block will have a P wave rate unrelated to the rate of the QRS complexes. This ECG has p waves conducted and

related to the QRS complexes; this ECG is not complete heart block. This ECG shows Brugada syndrome defined by a symptomatic patient with right bundle branch block (RBBB) or incomplete RBBB in leads V1 and V2 with concurrent ST segment elevation.

Learnings/What to Look for

- Age of manifestation of Brugada syndrome is typically 30-40 years; it occurs in families
- Most patients are asymptomatic
- ECG will show incomplete RBBB in V1/V2 with ST segment elevation—saddle or cove type. These findings may be transient
- Brugada may be the culprit in up to 4%–5% of cardiac arrests
- Mortality is high without placement of an ICD, as there is a high risk of sudden cardiac death

Pearls for Initial Management and Considerations for Transfer:

- Perform an ECG in all syncope patients
- Many ECG machines are not programmed to read Brugada syndrome
- In the syncopal patient, look at the ECG specifically for Brugada syndrome, as well as for WPW, prolonged QT, HCM, and other serious arrhythmias, as well as ischemia
- Patients who have had a syncopal episode from Brugada are by definition symptomatic and either should be transferred to the ED by EMS or a plan determined after phone consultation with an electrophysiology cardiologist before the patient leaves the urgent care center

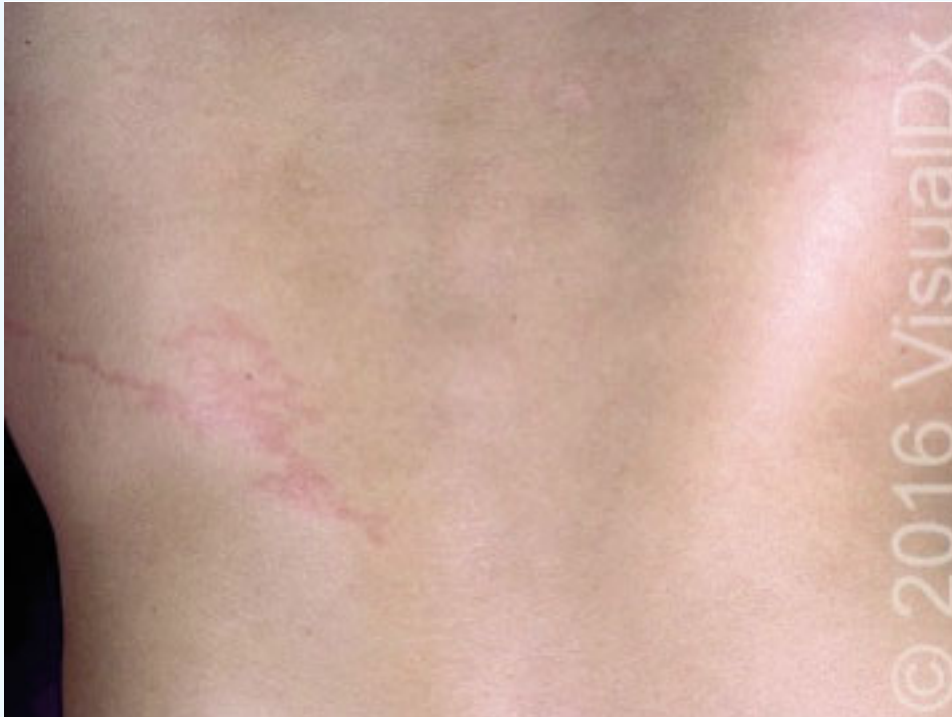Acknowledgment: Image provided by Amal Mattu, MD.

Correction: In the February 2019 issue of *JUCM*, we presented the case of a 55-year-old male with 3 hours of epigastric pain. Ultimately, he was diagnosed with an inferior STEMI. We would like to clarify that the ECG in question shows inferior STEMI with a rhythm being sinus with 2:1 block. These patients are at higher risk of arrhythmia including heart block; EMS should be activated immediately and the patient monitored until arrival.



A 37-Year-Old Man with Multiple Symptoms Following a Trip to Japan

Figure 1.



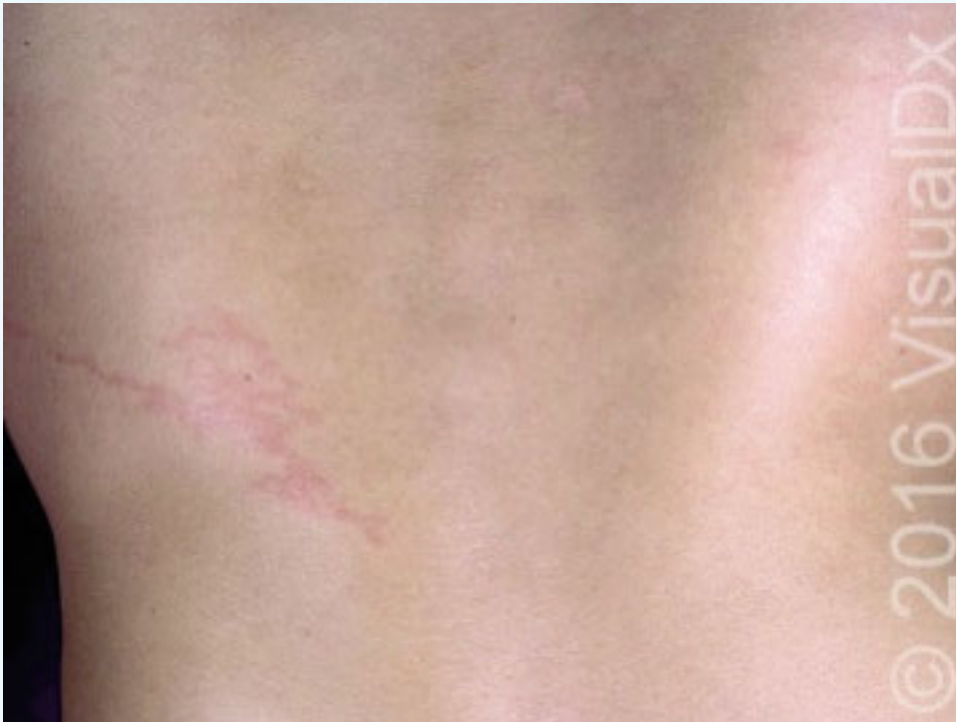Case

The patient is a 37-year-old man who presents to urgent care complaining of fever, nausea, and abdominal pain. He had attributed these symptoms to a recent trip to Japan, where he ate lots of new foods along with old favorites like sushi. However, he became concerned when a pruritic, serpiginous lesion appeared on his flank.

View the photo taken, and consider what your diagnosis and next steps would be. Resolution of the case is described on the next page.

THE RESOLUTION

Figure 2.

**Differential Diagnosis**

- Cutaneous larva migrans
- Gnathostomiasis
- Loiasis
- Strongyloidiasis

Diagnosis

This patient was diagnosed with gnathostomiasis, a helminth infection contracted after ingesting raw fish, frog, chicken, or pork infected with *Gnathostoma spinigerum* and other minor *Gnathostoma* spp.

Learnings

- Gnathostomiasis is endemic to parts of Asia and South/Central America
- Symptoms are thought to relate to the movement of the parasite through the body
 - Constitutional symptoms may occur when it moves through the wall of the stomach (2 days to 2 weeks after ingestion), and skin manifestations when it moves under the skin (3 to 4 weeks after ingestion)

- Cutaneous manifestations are not unlike loiasis, in which the patient complains of migratory cutaneous and subcutaneous swellings which may be amorphous or resemble cutaneous larva migrans (serpiginous)
- Patients may complain of pruritus, arthralgias and myalgias, fever, nausea, and abdominal pain. However, larvae can migrate through any organ and, therefore, nearly any physical symptom is possible (eg, right-upper-quadrant pain and transaminitis may occur as the larvae migrate through the liver)

Pearls for Urgent Care Management and Considerations for Transfer

- Albendazole and ivermectin have been shown to be curative for cutaneous symptoms
- Recurrence requiring retreatment is not uncommon

Acknowledgment: Images courtesy of VisualDx.